



**PRESENTING CLINICAL SIGNS**

History: On 8/1 and 8/2, would jerk himself awake, take deep breaths, and run around the house crying. Possible intermittent gallop sound.

DATE

8/5/22

**ECHOCARDIOGRAPHIC FINDINGS**

2D, M-mode, and Doppler study.

PERFORMED BY:

Sarah Pender, CVT

Left atrial size is normal. The mitral valve appears normal. Left ventricular wall thickness is normal. Left ventricular internal dimensions are normal. Left ventricular systolic function is hyperdynamic. The aorta and aortic valve are normal. Right atrial and right ventricular dimensions are normal. The tricuspid valve appears normal. The pulmonary artery and pulmonic valve are normal. No shunting lesions are visualized. No pericardial effusion or cardiac masses are seen.

INTERPRETED BY

Keith Blass, DVM,  
MS, DACVIM  
(Cardiology)

LA - 10.7 mm  
LA/Ao - 1.22  
IVSd - 4.1 mm  
LVPWd - 4.3 mm  
LVIDd - 9.8 mm  
LVIDs - 3.1 mm  
FS - 68%  
RA - 6.6 mm  
LVOT - 1.20 m/s  
RVOT - 1.15 m/s

PATIENT

Cheddar Miles

SPECIES

Feline

**ASSESSMENT/RECOMMENDATIONS**

Normal echocardiogram

BREED

This examination demonstrates no evidence of structural heart disease. As such, no reason for Cheddar's episodes earlier this week is appreciated in the image set.

DSH

No therapy is recommended based on this exam.

SEX

A recheck echocardiogram is recommended if new physical exam and/or clinical abnormalities suggestive of cardiac dysfunction develop.

MN

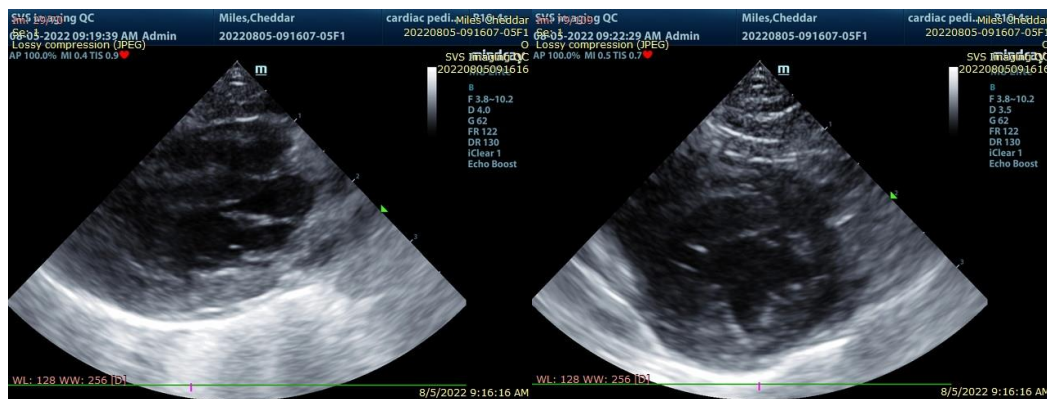
AGE

6 mo

WEIGHT

7.3 lb

HOSPITAL NAME

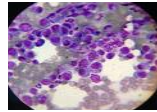


SVS Imaging QC

The information and recommendations provided are based on the images presented by the referring veterinarian. No evaluation can be communicated regarding pathology that was not visible in the image/video clips provided.

REFERRING VET

Dr. Narske



Thank you for this referral. If the clinical or image interpretation does not parallel your findings or if I can be of any further assistance please contact me.

**DATE**

8/5/22

**Keith Blass, DVM, MS, DACVIM (Cardiology)**  
KeithBlass@gmail.com  
631-804-5754

**PERFORMED BY:**

Sarah Pender, CVT

**INTERPRETED BY**

Keith Blass, DVM,  
MS, DACVIM  
(Cardiology)

**PATIENT**

Cheddar Miles

**SPECIES**

Feline

**BREED**

DSH

**SEX**

MN

**AGE**

6 mo

**WEIGHT**

7.3 lb

**HOSPITAL NAME**

SVS Imaging QC

**REFERRING VET**

Dr. Narske